

SYSTEMIC LUPUS ERYTHEMATOSUS PRESENTING WITH LUPUS NEPHRITIS

**Ahmed. Abd Elrahim⁴, A.M. Abd Elgyoum^{1,2}, H. Osman^{1,3}, A. Elzaki^{1,4}, E.Abd Elrahim¹,
Ali Hassan¹, Suhaeir Abdel Satatr¹ & Salah.O.Elmahi⁵**

1 Taif University, college of applied medical science, P O Box 2425 post code 21944 .Taif KSA

2 National Ribat University, Nile Street Burri, Postal Code 11111, Khartoum Sudan

3 Colleges of Medical Radiologic Science, Sudan University of Science and Technology P.O.Box 1908, Khartoum.
Sudan

4Faculty of Radiology Science and Medical Imaging, Alzaiem Alazhari University, P.O.Box 1432 Khartoum North,
Sudan

⁵Salah Medical center ,Khartoum North, Sudan

Address: Faculty of Radiology Science and Medical Imaging, Alzaiem Alazhari University, P.O.Box 1432 Khartoum
North, Sudan

(Received on Date: 11th November 2015

Date of Acceptance : 26th December 2015)

ABSTRACT

Systemic lupus erythematosus often abbreviated as SLE or lupus, is a systemic autoimmune disease, in which the body's immune system mistakenly attacks healthy tissue. Lupus is characterized by the presence of antibodies against a person's own proteins; these are most commonly anti-nuclear antibodies, which are found in nearly all cases. These antibodies lead to inflammation. We reported case of 36-year-old female Sudanese patient came to our center complaining of backache, generalized body ache and pain, easy fatiguability; joint pain and swelling; particularly knee joints; loin pain, oligouria, suprapubic pain and burning micturition.

Keywords: Systemic lupus erythematosus (SLE), hypersensitivity, Antinuclear antibodies (ANA).

No: of Figures : 2

No:of References : 13

INTRODUCTION

Systemic lupus erythematosus: often abbreviated to SLE or lupus, is a systemic autoimmune disease (or autoimmune connective tissue disease) that can affect any part of the body. As occurs in other autoimmune diseases, the immune system attacks the body's cells and tissue, resulting in inflammation and tissue damage.^[1,13] It is a Type III hypersensitivity reaction in which antibody-immune complexes precipitate and cause a further immune response. SLE most often harms the heart, joints, skin, lungs, blood vessels, liver, kidneys, and nervous system. The course of the disease is unpredictable, with periods of illness (called *flares*) alternating with remissions. The disease occurs nine times more often in women than in men, especially in women in child-bearing years ages 15 to 35, and is also more common in those of non-European descent.^{[2][3][4]} There is no cure for SLE. It is treated with immunosuppression, mainly with cyclophosphamide, corticosteroids and other immune suppressants. SLE can be fatal. The leading cause of death is from cardiovascular disease due to accelerated atherosclerosis. Survival for people with SLE in the United States, Canada, and Europe has risen to approximately 95% at five years, 90% at 10 years, and 78% at 20 years,^[4] and now approaches that of matched controls without lupus. Childhood systemic lupus erythematosus generally presents between the ages of 3 and 15, with girls outnumbering boys 4:1, and typical skin manifestations being butterfly eruption on the face and

photosensitivity.^[1] Lupus is Latin for wolf. In the 18th century, when lupus was just starting to be recognized as a disease, it was thought that it was caused by the bite of a wolf.^[5] This may have been because of the distinctive rash characteristic of lupus. (Once full-blown, the round, disk-shaped rashes heal from the inside out, leaving a bite-like imprint.)

CASE REPORT

We reported 36-year-old female Sudanese patient came to our centre complaining of backache, generalized body ache and pain, easy fatiguability; joint pain and swelling; particularly knee joints; loin pain, oligouria, suprapubic pain and burning micturition. She was rather ill, pale; not jaundiced or cyanosed. There were hand joints and wrists pain (MCP joints) was swollen and rather tender. There were some hyper pigmented scaly areas on the face and lower limbs. Routine blood examination identified normocytic normochromic anemia with elevated erythrocyte sedimentation rate (ESR). C-reactive protein was positive, and renal function test (RFT) showed increased urea, creatinine and uric acid, urine general indentified uncountable pus cells. Urine for culture showed E-coli. ANA was positive and antids DNA was positive. Blood glucose and liver function test (LFT) were normal. Ultrasound of the abdomen revealed enlarged kidneys with decreased cortical echogenicity consistent with lupus nephritis, in addition to slightly enlarged spleen, otherwise the findings were normal; Figure ^[1]

She was given the following medications;

Prednisolone 1mg/kg, Ceftriaxone 2gm b.d for 10 days, Haematonics, Ca ++ and D3, PPI + pantoprazol and we avoided NSAID, Two weeks later follow up investigations were showed decreased ESR level , CRP became negative, and urinary tract infection was subsided ,Six weeks later we found that everything was normalized for laboratory investigations and ultrasound of the abdomen was normal Figure [2].Then steroid was tapered to 5 mg/day with maintenance ca ++ +D₃ and PPI every other day.Later on steroid was further reduced to 5 mg every other day and azathioprine 50mg/day was added Steroid sparing agent. Now the patient is well and on regular follow up.

Diagnosing Systemic Lupus Erythematosus

There is no definitive test for diagnosing SLE. That being said, the antinuclear antibodies ANA test is one commonly used to identify whether lupus could be a proper diagnosis. Antinuclear antibodies (ANA) are eventually found in more than 98 percent of people with lupus. However, some patients test positive for ANA and do not have lupus, while others who test negative for ANA still may have lupus. [7]

Systems Affected by SLE

Lupus often affects many different systems in the body, and therefore, if you do have lupus, the symptoms and signs that you may experience will depend heavily on which part of the body is being affected by the disease, but here is a thorough yet abbreviated list; Brain and Nervous System:

Persistent and unusual headaches, memory loss,

or confusion.

Ophthalmologic-Eyes: Lupus can damage nerves and blood vessels in the eye, leading to dry or puffy eyes, and increasing sensitivity to light. [7]

Oral-Mouth: Sores inside the mouth are a common symptom of lupus.

Dermatologic-Skin: Lupus may cause skin rashes, and is known for its distinctive “butterfly” rash on the face usually over the cheeks and bridge of the nose. These rashes can be exacerbated by sun exposure. You may also experience hives or sores which would also worsen with sun exposure. Sudden and unexplained hair loss could also signify lupus.

Cardiopulmonary-Lungs: Lupus can damage the lungs through pleurisy and pneumonitis (inflammation), or pulmonary emboli, resulting in shortness of breath and pain in the chest from deep breathing. . [7]

Renal System- Kidneys: About half of systemic lupus erythematosus (SLE) patients will develop some form of kidney inflammation, called lupus nephritis. This inflammation can lead to kidney failure, but like most lupus symptoms the effect on the kidneys is quite variable and hard to predict. Increased protein (showing as blood) in the urine, swelling of the feet and legs, and high blood pressure can be indicators that the kidneys may be affected. .

[7]Gastrointestinal-Stomach &

Digestion: Lupus can cause or exacerbate ulcerative colitis, pancreatitis, and liver conditions, resulting in nausea, vomiting,

recurring and persistent abdominal pain, bladder infections, and blood in urine. Reproductive: Lupus or SLE can cause fertility issues. Hematologic-Circulation in the Fingers, Toes, and Tip of the Nose: If your fingers turn white or blue with exposure to cold or during stressful situations, it can be caused by a constricting of the small blood vessels in those areas. This is called Raynaud's phenomenon, a condition closely associated with lupus. Musculoskeletal-Legs, Joints, and Feet: Persistent joint pain and swelling is a common lupus symptom. Legs and feet may also swell. . [7]

DISCUSSION

Lupus nephritis occurs in most patients with systemic lupus erythematosus (SLE). The disease typically presents within the first two years after SLE diagnosis, with nearly half of all patients developing it in the first year. [6]Overall, an estimated 5 to 20 percent of

patients, even those who receive appropriate treatment, develop end-stage renal disease requiring dialysis or transplant within 10 years of diagnosis. Thus, identify ingbiomarkers that predict damage or nephritis flares as well as the best possible treatment to prevent long-term damage are critical research focuses in this area. [8,9,10] Pathologic changes of the heart ranging from focal areas of mild acute inflammation to severe post inflammatory fibrosis may be noted in all layers of the heart as well as coronary and pulmonary arteries. The classical valvular abnormality is the verrucous Libman-Sacks lesion, originally described in 1924. Valvular abnormalities have been documented in up

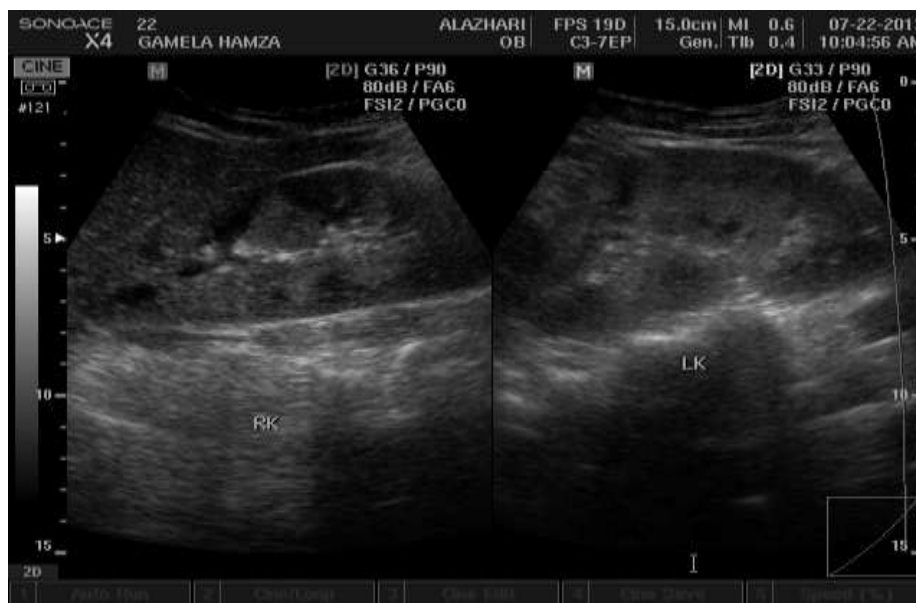

Figure (1): TAS showing Rt & Lt kidney with poor c/m differentiation
 2016 January Edition | www.jbino.com | Innovative Association

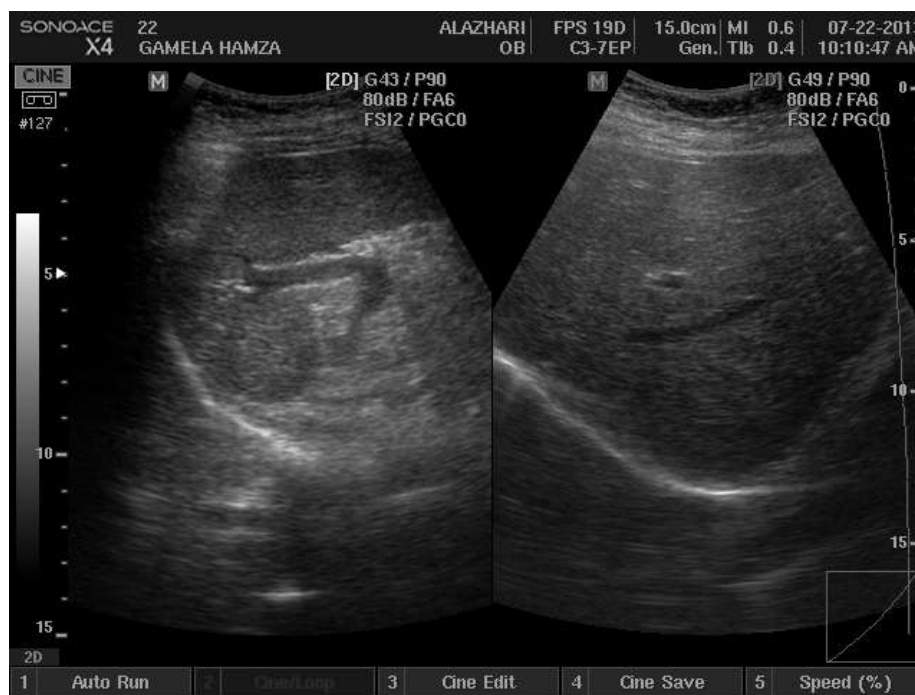


Figure (2): TAS showing liver and spleen

to 35% of patients with lupus. This percentage rises to 48% among lupus patients with antiphospholipid antibodies.[11]

Renal involvement is reported to occur in 61-81% of patients with SLE. A renal biopsy is necessary to confirm and classify the diagnosis of lupus nephritis and hence to guide treatment.[12]. End-stage renal disease or death has been reported in 20-50% of children with this form of nephritis at 10-year follow-up due to progressive renal parenchymal injury. [12]

REFERENCES

"Harrison's Internal Medicine, 17th ed. Chapter 313. Systemic Lupus Erythematosus". Accessmedicine.com. Retrieved 2011-08-06.

"LUPUS FOUNDATION OF AMERICA". Retrieved 2007-07-04.

Ala Mohammed Abd Elgyoum Mohamed Ahmed, Abd Allah Mohammed Jaber, Amin A. E. Elzaki, Doppler Ultrasonography Of The Kidneys In Diabetic Patients, Asian Journal of Medical Radiological Research, Vol-1 Issue- 1, P18 -21, Jun 2013.

Anisur Rahman and David A. Isenberg (February 28, 2008). "Review Article: Systemic Lupus Erythematosus". *N Engl J Med* **358** (9): 929–939. doi:10.1056/NEJMra071297. PMID 18305268.

Blotzer JW (June 1983). "Systemic lupus erythematosus I: historical aspects.". *Md State Med J* **32** (6): 439–41. PMID 6348430.

Fiehn C, Hajjar Y, Mueller K, et al. Improved clinical outcome of lupus nephritis during the past decade: Importance of early diagnosis and treatment. *Ann Rheum Dis.* 2003;62(5):435-439.

Houssiau FA. Management of Lupus Nephritis: An Update. *J Am Soc Nephrol.* 2004;15(10):2694-2704.

James, William; Berger, Timothy; Elston, Dirk (2005). *Andrews' Diseases of the Skin: Clinical Dermatology.* (10th ed.). Saunders. ISBN 0-7216-2921-0.

Lupus nephritis: prognostic factors and probability of maintaining life-supporting renal function 1 years after the diagnosis.

Gruppo Italiano per lo Studio della Nefrite Lupica (GISNEL). *Am J Kidney Dis.* 1992;19(5):473-479.

Molly fund, systemic-lupus-erythematosus, 2007 -2015

Nesher G, Ilany J, Rosenmann D, Abraham AS. Valvular dysfunction in antiphospholipid syndrome: Prevalence, clinical features, and treatment. *Semin Arthritis Rheum.* 1997;27:27–35. [PubMed].

Seshan SV, Jennette JC. Renal disease in systemic lupus erythematosus with emphasis on classification of lupus glomerulonephritis: advances and implications. *Arch Pathol Lab Med.* 2009;133(2):233-248.

Silverman ED. Pediatric systemic lupus erythematosus. In: Rudolph AM, Rudolph CD, Hostetter MK, Lister G, First L, Gershan A, editors. *Rudolph's Pediatrics.* 21st ed. New York: McGraw-Hill; 2003. pp. 848–51.